

Early results after ProDisc-C cervical disc replacement

RUDOLF BERTAGNOLI, M.D., JAMES J. YUE, M.D., FRANK PFEIFFER, M.D.,
ANDREA FENK-MAYER, M.D., JAMES P. LAWRENCE, M.D., TRACE KERSHAW, PH.D.,
AND REGINA NANIEVA

*Department of Orthopaedic Surgery, Spine Center, St. Elizabeth Klinikum, Straubing, Germany; and
Department of Orthopaedic Surgery and Rehabilitation, Yale University, New Haven, Connecticut*

Object. Cervical anterior decompression and total-disc replacement is currently being investigated as an alternative treatment in patients with symptomatic intervertebral cervical spondylosis with and without radiculopathy. The authors prospectively investigated the safety and efficacy of using the ProDisc-C disc for cervical arthroplasty in the treatment of symptomatic cervical spondylosis.

Methods. Sixteen patients in whom a diagnosis of symptomatic cervical spondylosis had been established were prospectively treated with complete anterior cervical discectomy and ProDisc-C cervical disc arthroplasty. Overall 12 single- and four two-level procedures were performed (20 prostheses). Patients underwent pre- and multiple postoperative assessments (3 and 6 weeks and 3, 6, and 12 months).

The median age of all patients was 50 years (range 32–60 years). Levels of surgery included seven C5–6, six C6–7, and three C4–5. Neck and arm pain as well as disability scores were significantly improved by 3 months and remained significantly improved at 1 year. No additional fusion surgeries were necessary at the affected or unaffected levels. Radiography revealed an affected disc motion from 4 to 12°. No surgery- or device-related complications were documented.

Conclusions. Analysis of preliminary results involving ProDisc-C arthroplasty indicates significant improvement in pain and functional outcome scores. No spontaneous fusions at the level of surgery or at adjacent levels were noted. Long-term follow-up studies will be necessary before more definitive treatment recommendations can be formulated.

KEY WORDS • cervical spondylosis • artificial disc replacement • ProDisc-C • total-disc replacement • arthroplasty

ANTERIOR cervical discectomy and fusion is a common treatment for symptomatic intervertebral cervical spondylosis with and without myelodisculopathy.^{1,2,4–23,25–30,33–36,39,40,42–44,47,51,53,54,57,58,63} Although the results of anterior cervical procedures such as anterior cervical fusion involving single-level and/or intervertebral discectomy and interbody fusion have yielded satisfactory results at the index level of spondylosis, the authors of recent studies have reported moderately high rates of repeated operation to treat adjacent-level disease.^{45,48–50,59} Other fusion-associated detrimental effects include a loss of segmental ROM, hardware-related complications, and nonunion. Total-disc arthroplasty or replacement has recently been studied by investigators assessing several implant designs in an attempt to overcome the shortcomings of fusion.^{24,41,55,60}

Recent advances in material and implant design have enabled the development of a novel implant design, the

ProDisc-C (Synthes Spine, Paoli, PA), which follows the principles of providing immediate implant stability, ease and safety of insertion, single- or multisegmental device-related capabilities, minimal endplate disruption, and optimization of functional ROM. These principles and design characteristics were prospectively explored in the present investigation.

Clinical Material and Methods

Patient Population and Evaluation

Prospective data were compiled for single- and two-level ProDisc-C procedures performed between December 2002 and March 2003. Sixteen patients were enrolled in this study. Data obtained in these patients comprised the initial human safety and efficacy information for the European CE application. The data reported in this study were not part of a larger multicenter trial. Clinical investigation review board approval was received prior to enrollment. Demographic data are summarized in Table 1.

Inclusion criteria included one- or two-level recalcitrant cervical spondylosis demonstrated on plain radiography and MR imaging (Fig. 1). Two categories of patients were enrolled into the study: 1) those with severe axial neck pain

Abbreviations used in this paper: AP = anteroposterior; GEE = generalized estimating equation; MR = magnetic resonance; ODI = Oswestry Disability Index; ROM = range of motion; VAS = visual analog scale.

TABLE 1
Summary of demographic data

Variable	Male	Female	Total
no. of cases	8	8	16
age (yrs)			
mean	45.6	51	48.3
median	45	52.5	49
range	33–60	32–59	32–60

of greater than 6 months' duration and secondary to intervertebral degenerative disc disease without radicular and/or myelopathic symptoms; and 2) those with persistent radicular symptoms of greater than 2 months' duration with axial neck pain and absent or minimal clinical signs of myelopathy. All patients were between the ages of 18 and 60 years. Exclusionary criteria included pregnancy, rheumatoid arthritis or other inflammatory or connective tissue disorders, prior fracture or fusion, tumor, metabolic or systemic disease, pertinent metallic allergies, posterior facet joint arthropathy, moderate or severe myelopathy, posterior vertebral body–induced spinal cord compression, chronic infections, osteoporosis, and involvement in Workers' Compensation and/or litigation.

Surgery was performed after complete clinical and neuroimaging/radiographic assessments including AP/lateral/flexion/extension radiography; computerized tomography in the axial, sagittal, and coronal planes, MR imaging, and/

or discography. All procedures were performed by the senior author (R.B.) at a single institution. Bias as to outcome was avoided because patients' responses to questionnaires were used as the primary outcome measurements. Secondary parameters requiring measurements such as disc height of the affected level, adjacent-level disc height, and the degree of motion were performed by a trained technician blinded to the hypothesis of the primary investigators. The data were collected and compiled by an independent technician, blinded to the hypothesis of the primary investigators. After the aforementioned data had been compiled, they were analyzed by an independent examiner who had no interaction with the patients or involvement with the surgical procedures during this study.

Surgical Technique

The surgical approach was consistent throughout the study. The patients were placed supine on a fluoroscopic imaging table with their arms at their sides and shoulders taped to allow for fluoroscopic imaging. After positioning, fluoroscopic images were obtained in AP and lateral planes to determine the level of diseased disc. A standard left-sided approach was undertaken to access the anterior cervical spine. A specialized anterior spinal retractor system, Cervical SynFrame (Synthes Spine), was used to assist in exposure. A complete single- or two-level anterior discectomy was performed. When two-level segmental disc replacement was required, the most distal segment

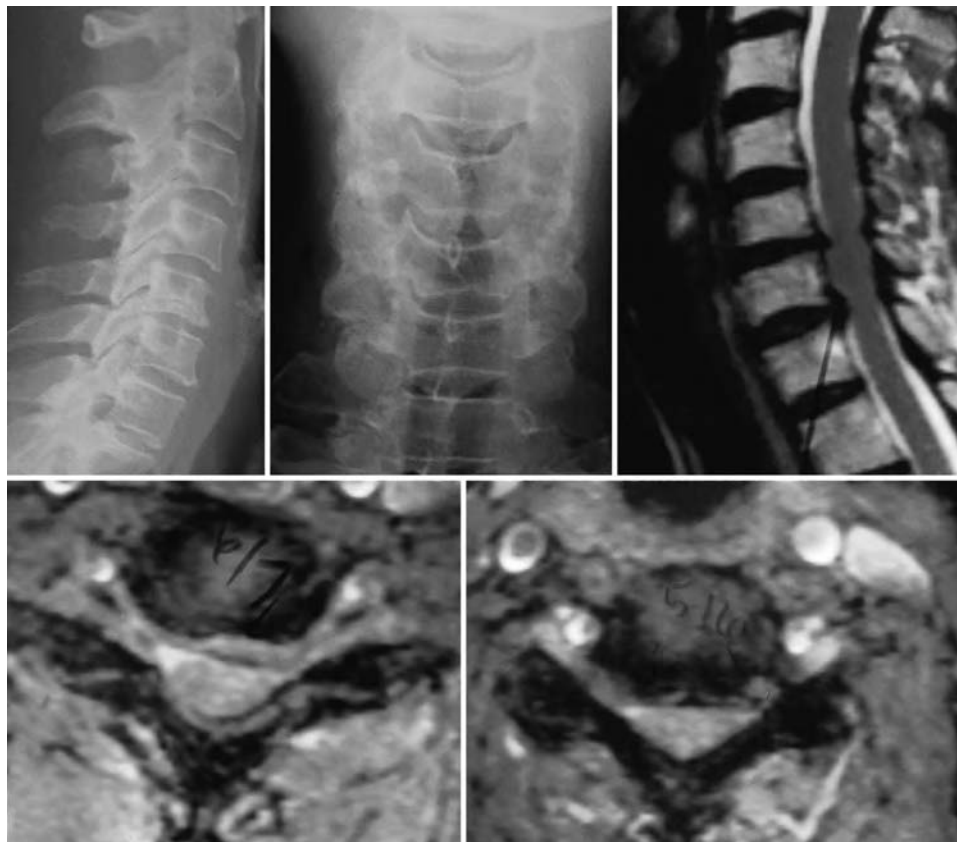

FIG. 1. Preoperative imaging studies. Lateral (*upper left*) and AP (*upper center*) radiographs and sagittal MR image (*upper right*). Axial MR images at C5–6 (*lower left*) and C6–7 (*lower right*).

Early results after ProDisc-C arthroplasty

was treated first to completion and the more proximal-level discectomy was then performed.

When indicated, the posterior longitudinal ligament was released to allow for excision of extruded disc material and/or to determine the appropriate intervertebral disc height. Only the cartilaginous portion of the vertebral endplate was removed. Preparation of the endplates was performed using standard and ring curettes and endplate elevators. A burr was used only when endplate leveling could not be achieved with appropriate curettes.

Lateral fluoroscopically assisted trialing was performed to determine appropriate size with regard to height and AP diameter. Adequate central/midline location of the prosthesis was confirmed using AP fluoroscopy prior to making keel cuts. After the midline was determined, keel cuts were made using the keel cutting chisel guided over the prosthesis trial. The chisel and trial piece were then removed and the appropriate-sized final prosthetic endplates were inserted to an adequate depth under lateral fluoroscopic guidance. The endplates were then distracted and the polyethylene implant was inserted. Following this, AP and lateral fluoroscopy were performed to confirm the appropriate positioning and size of the implant. No other procedures were preformed at that time of the index procedure.

Postoperatively, a soft cervical collar was worn for 4 weeks, and patients were allowed to move in these collars as tolerated. After these initial 4 weeks, the soft collar therapy was discontinued, and patients were allowed to engage in normal activities of daily living including driving. After 6 weeks, patients were allowed to return to all normal activities except contact sports on a permanent basis. Postoperative oral pain medications were administered as needed. In the first 8 weeks antiinflammatory medication therapy was not advised. Instead, either narcotic agents or other medications such as tramadol were given.

Outcome Measures

Patients were assessed preoperatively and postoperatively at 3 and 6 weeks and at 3, 6, and 12 months. Preoperative and postoperative disability and pain levels were assessed using the ODI³¹ modified for the cervical spine and the VAS, respectively. Additional clinical parameters included analysis of pre- and postoperative satisfaction, general neck pain, radicular pain, medication usage, and complications. Patient satisfaction was rated as the following: completely satisfied (a score of 1 [no arm or neck pain]); satisfied (score of 2 [occasional arm or neck pain < once per day not requiring medication of any type]); and unsatisfied (score of 3 [neck or arm pain > once per day requiring medication usage of any type]). Neck and radicular pain were assessed in terms of intensity and frequency (score range 0 [none]–10 [maximal]). Medication usage was also noted.

Radiographic Assessment

Preoperative and postoperative radiographs, including AP, lateral, flexion–extension, and lateral bending films, were obtained in all patients (Fig. 2 upper left and right and center left and right). Intervertebral disc heights of affected and adjacent levels, angular intervertebral disc motion, and subsidence were measured using digitized images and appropriate computer software (Medimage Software; Vepro Computersysteme GmbH, Pfungstadt, Germany). Measure-

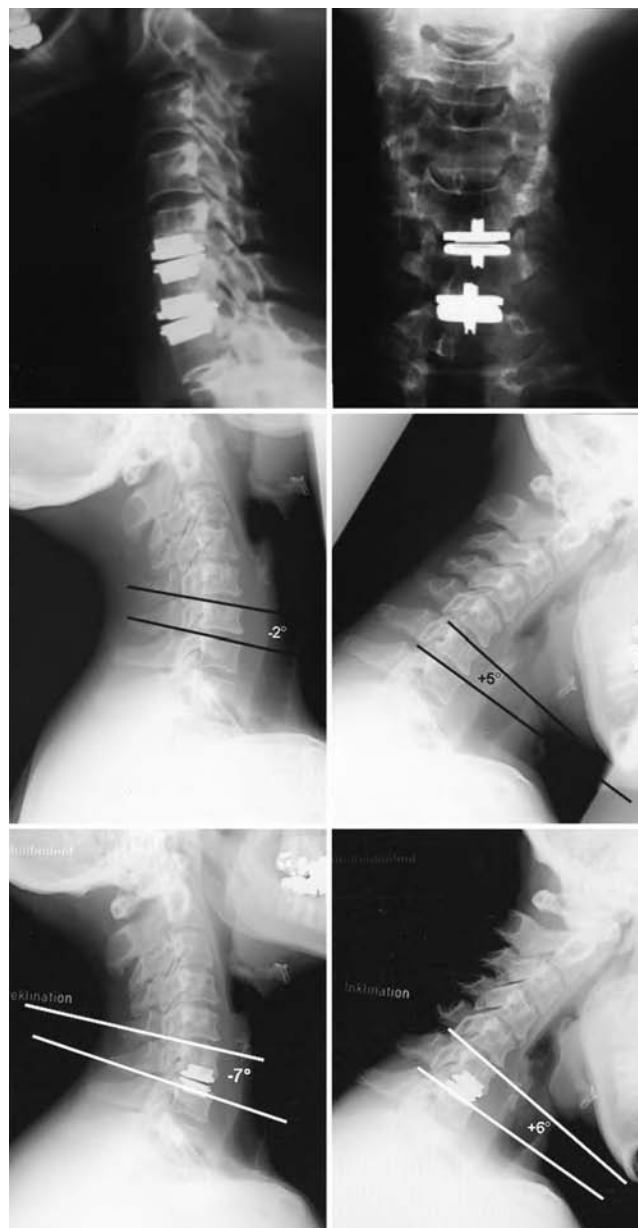


FIG. 2. Lateral (upper left) and AP (upper right) 1-year postoperative radiographs. Preoperative flexion (center left) and extension (center right) radiographs showed a total motion of 7°. One-year postoperative flexion (lower left) and extension (lower right) radiographs demonstrated a total motion of 13°.

ments were performed by a single reviewer three times and a mean score was determined for angle and length measurements. Angular and length measurements were performed. Two separate reviewers (an attending spine surgeon not involved in the surgery and an attending radiologist) assessed all pertinent radiographs for device-related loosening, dislodgment, and/or subsidence.

Statistical Analysis

To assess changes over time, mixed-model analysis was conducted for the continuous variables (ODI, VAS, ROM, neck pain intensity, neck pain frequency, leg pain intensity,

leg pain frequency values), and GEEs were conducted for patient satisfaction. Mixed-effects models and GEEs are advantageous because they use all available data obtained in all participants (rather than dropping those for whom data are missing or imputing missing values). In addition, they incorporate serial correlations among observations over time, which results in less bias than that achieved by traditional repeated-measures analysis of variance models that assume that repeated measures are equally correlated over time and have constant variance. Three research questions were of primary interest for this study: 1) whether there was a significant change from presurgery to 3 weeks postsurgery (proximal effect); 2) whether that change was sustained 1 year postoperatively (distal effect); and 3), finally, whether there was continued change from 3 weeks to 1 year postsurgery. Therefore, the following three planned contrasts were conducted within the mixed-effects models and GEE analyses: 1) comparing presurgery with 3 weeks postsurgery scores; 2) comparing presurgery with 12 months postsurgery scores; and 3) comparing 3 weeks with 12 months postsurgery scores. Preoperative patient satisfaction scores were not obtained. Therefore, the overall time effect was used to assess if there were overall changes from the 3 weeks to the 12 months after surgery.

Results

Demographic Data

The demographic results are summarized in Tables 1 and 2. Follow-up criteria were fulfilled in all patients in the study. The median follow-up period was 12.7 months (range 12–14 months). There were eight men and eight women. The overall median age was 50.5 years. The overall median duration of preoperative pain was 50 months (range 6 weeks–400 months). Surgery was performed at C5–6 in seven patients, C6–7 in six, and C4–5 in three.

Two patients (12.5%) had undergone prior anterior cervical disc surgery, in both of whom the Bryan disc had been placed and who experienced adjacent-level degenerative disc changes. One patient presented 2.5 years and the other 2 years after application of the Bryan disc (Medtronic Sofamor Danek, Memphis, TN). Four of our patients suffered axial neck pain alone and 12 patients experienced both neck and radicular or myelopathic symptoms. Nineteen percent of patients were smokers.

Clinical Outcomes

Clinical outcomes are summarized in Fig. 3 *upper* and *center*. Results of the planned contrasts involving the mixed-effects models showed significant decrease in ODI scores from 25% preoperatively to 15% at the 3-week follow up (F = 8.45, p < 0.005). This clinical improvement (16.5%) was sustained at 1 year (F = 5.31, p < 0.05); however, there was no significant increase from the 3-week to 1-year scores (F = 0.16, p = 0.69), indicating that the decreased ODI score occurred primarily by 3 weeks after surgery. Similarly, mean preoperative VAS scores (7.7) showed significant decreases compared with the 3-week follow-up score (2.3) (F = 27.75, p < 0.001). That change (4.4) was sustained at 1 year after surgery (F = 9.81, p < 0.005); however, there was no significant increase between 3-week and 1-year follow-up scores (F = 3.03, p = 0.09).

TABLE 2
Cervical level at which the artificial disc was placed

Level of Op	No. of Cases
C5–6	7
C6–7	6
C4–5	3

Preoperative ROM did not significantly change compared with that demonstrated 3 weeks after surgery (F = 0.066, p = 0.42), but a delayed change was evident between preoperative ROM and 1-year follow-up status (F = 5.50, p < 0.001). A significant change occurred between 3-week and 1-year ROM values (F = 18.71, p < 0.001).

Preoperative neck pain intensity and frequency significantly decreased when preoperative 3-week follow-up values were compared (both p < 0.001), and this change was sustained at the 1-year follow-up examination (both p < 0.005; Table 3). Although there was a slight increase in neck pain intensity and frequency between 3-week and 1-year follow-up values (both p < 0.05 compared with preoperative values), there was no significant increase in neck pain intensity and frequency when comparing 3-week and 1-year follow-up values (p = 0.36 and 0.38, respectively). Therefore, neck pain significantly decreased initially and then slightly increased from 3 weeks

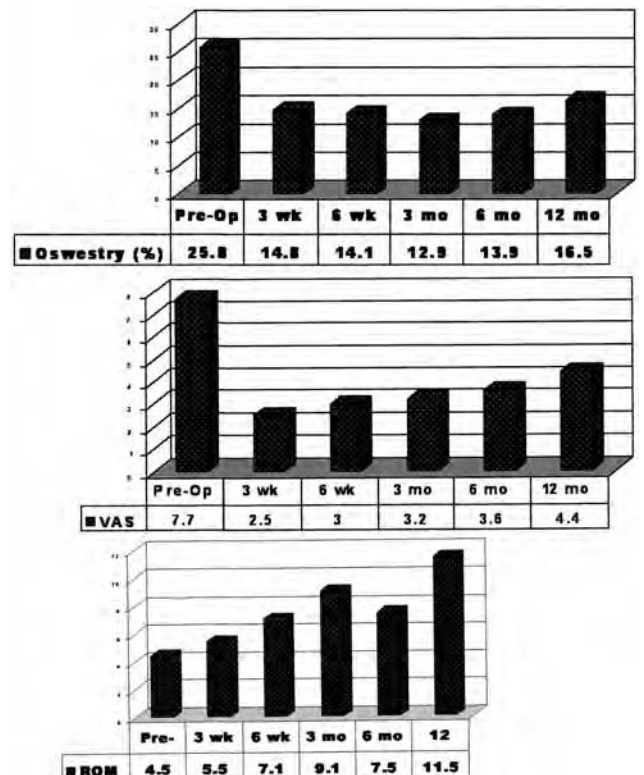


FIG. 3. Bar graphs. *Upper*: Preoperative, 3- and 6-week, and 3-, 6-, and 12-month postoperative ODI values. *Center*: Preoperative, 3- and 6-week, and 3-, 6-, and 12-month postoperative VAS scores. *Lower*: Preoperative, 3- and 6-week, and 3-, 6-, and 12-month postoperative ROM values.

Early results after ProDisc-C arthroplasty

TABLE 3
Summary of pain-based VAS scores preoperatively and at five follow-up intervals*

Interval	Neck Pain		Arm Pain	
	Intensity	Frequency	Intensity	Frequency
preop	8.1	8.6	6.9	7.1
3-wk	2.5	2.1	2.5	2.3
6-wk	3.8	4.2	3.3	2.9
3-mo	3.9	4.3	2.6	3.6
6-mo	3.9	5.6	2.4	2.8
12-mo	5.2	5.2	3.5	3.4

* Scores range from 1 (no pain) to 10 (greatest pain).

to 1 year after surgery, but it remained significantly lower than the preoperative level. There were significant decreases in arm pain intensity and frequency when comparing preoperative and 3-week follow-up values (both $p < 0.001$), and this change was sustained at the 1 year follow-up examination (both $p < 0.005$).

In terms of subjective outcomes, patients were satisfied (21.4%) or completely satisfied (78.6%) at the 3-week and satisfied (36.4%) or completely satisfied (63.6%) at the 1-year follow-up examination (Table 4). No patients reported being unsatisfied at any time during the follow-up period. According to GEE analyses, there was no significant change in patient satisfaction from the 3-week to 1-year follow up ($\chi^2 = 0.92$, $p = 0.34$).

Medication usage including nonsteroidal antiinflammatory drugs, narcotic agents, and morphine derivatives (tramadol) was decreased significantly after surgery (Table 5). Because of the small number of patients, statistical differences between those who had undergone prior cervical surgery and those who had not undergone prior surgery could not be performed; however, outcomes scores improved the least in the two patients who had undergone prior surgery.

Radiographic Assessment

The median preoperative height of the affected disc was 3 mm, and the mean postoperative height was 8 mm ($p < 0.001$). Motion of the affected discs was increased from 4° preoperatively to 12° postoperatively ($p < 0.004$; Fig. 3 lower). The heights of the adjacent-level discs were not significantly changed. There were no cases of subsidence, loosening, dislocation, or failure of metallic or polyethylene components. Lastly, we observed no spontaneous fusions at the affected or the adjacent levels.

Intraoperative Complications

Device-Related Complications. We observed no device-related complications. Loosening, subsidence, and migration of the implant as well as metallic or polyethylene failure, allergic rejection/reaction, visceral or neurological injuries caused by the implant components, and/or infection were absent.

Approach-Related Complications. Approach-related complications such as intraoperative fractures, hematomas, dural tears/leaks, postoperative airway compromise, esopha-

TABLE 4
Summary of patient satisfaction

Variable	Follow-Up Interval (%)				
	3-Wk	6-Wk	3-Mo	6-Mo	12-Mo
completely satisfied	78.6	81.8	86.7	78.6	63.6
satisfied	21.4	18.2	13.3	21.4	36.4
unsatisfied	0.0	0.0	0.0	0.0	0.0

geal or tracheal disruption, laryngeal nerve injury, and/or sympathetic nerve dysfunction were also not observed.

Autofusion/Ectopic Bone Formation. We observed no spontaneous fusions at the affected or adjacent levels.

Discussion

Although the initial clinical application of intervertebral disc arthroplasty is often credited to Fernstrom,³² the first published report involving application of the Fernstrom device was reported in 1964 by Reitz and Joubert⁵² who performed 75 cervical disc arthroplasties in patients with intractable headache and cervicobrachialgia. The patients were followed for less than 1 year and no long-term data were provided. There were no reported neurological complications or implant sublaxations and the group reported preservation of the motion at the involved levels.

In 1966 Fernstrom³² reported on an endoprosthesis composed of a stainless steel ball designed to be inserted into the disc center following laminectomy. Although this prosthesis was primarily designed for the lumbar spine, several were inserted into the cervical spine. Thirteen cervical disc prostheses were implanted in eight patients. These prostheses were 6 to 11 mm in diameter, or 1 mm greater than the transdiscal diameter. The cervical discs were removed via an anterior approach and the prostheses were placed following discectomy. Fernstrom's report contained data that had been collected for no more than 12 months, and all outcomes were satisfactory. Concerns regarding hypermobility and migration of the ball into the cancellous bone of the vertebrae, however, caused the technique to be abandoned.

Cervical arthroplasty was also reported by several other authors. Stefee⁵⁶ reported on one patient in whom he had placed two cervical prostheses of his design. The construct was a three-level device with prostheses at the end of an autograft strut at the disc level. The placement of methylmethacrylate cement in the cervical spine after anterior cervical discectomy was reported in 1985 by Ale-

TABLE 5
Medication usage*

Frequency	NSAID (%)		Narcotics (%)		Tramadol (%)	
	Preop	12 Mos	Preop	12 Mos	Preop	12 Mos
none	5.8	59.0	83.0	90.0	74.0	79.0
occasional	23.7	12.0	0	0.1	4.9	7.8
regular	49.5	28.7	15.8	8.9	21.0	12.8

* NSAID = nonsteroidal antiinflammatory drug.



FIG. 4. Image of the ProDisc-C prosthesis.

mo-Hammad.³ The technique involved the drilling or curettage of two cavities in the upper and lower vertebral surface and cautious placement of acrylic. Five patients were followed for 24 to 36 months, and the author did not comment on preservation of motion at the treated level. Other authors have described the use of acrylic within hollowed spaces of adjacent vertebral surfaces to create a concave mass allowing segmental motion, but no results have been published.

In 1998 Cummins, et al.,²⁴ reported pain relief in six of 20 patients in whom the Cummins artificial cervical joint, consisting of a moveable stainless steel ball-and-socket joint was implanted. The authors noted biomechanical stability and the lack of wear-related debris at follow-up

examination. Because the screws were inserted in the vertebral bodies, the device could not be used at multiple levels. The Cummins prosthesis was adapted to allow improved motion.

In 2003, Wigfield, et al.,⁶⁰⁻⁶² published results derived from a 2-year pilot study involving 15 patients with a history of cervical radiculopathy or myelopathy and confirmed disc herniation. All patients underwent decompressive surgery via an anterior approach as well as single-level replacement with the modified Cummins prosthesis (presently called the Bristol or Prestige prosthesis [Medtronic Sofamor Danek]) and were followed for 24 months. The device was stable in 15 of 16 patients, and motion was preserved in all but one case. Arm pain was improved in 46%, neck pain in 45%, and neck disability index was improved in 31% of patients.

Goffin, et al.,^{37,38} published their results after implantation of the Bryan Cervical Prosthesis in patients with single-level degenerative disc disease. This prosthesis consists of a polyurethane nucleus within two titanium-alloy shells. The device was inserted into 146 patients. Examination of intermediate follow-up data for cases involving single-level treatment indicated excellent and good results in 78% at 1 year and 69% at 2 years. In two-level cases, excellent and good results at 1 year were reported in 79% of patients. At 2 years 93% of patients exhibited flexion-extension motion at the treated levels of greater than or equal to 2°. The presence of lateral ectopic bone formation was noted but not elaborated on because of the preliminary status of the data.

Although long-term prospective and randomized studies will be necessary to provide optimal Level 1 clinical data to determine the advantages and disadvantages of either fusion or arthroplasty, our intermediate results involving the ProDisc-C device are very encouraging and represent statistically significant improvements in clinical and radiographic parameters. Of note, we did observe a




FIG. 5. Images of the Keel cutting chisel.

Early results after ProDisc-C arthroplasty

slight statistical trend toward higher VAS and ODI scores at our follow-up interval and we will closely follow this trend in longer-term follow-up studies.

The specific advantages of the ProDisc-C device and its application technique include the absence of anterior plate-like fixation hardware, preservation of osseous endplates, immediate keel fixation stability, and the possibility of multilevel application. Biomechanically, the ProDisc-C implant is considered to represent a ball-and-socket/semiconstrained design with a fixed axis of rotation (Fig. 4). The surgical technique is relatively atraumatic because of the limited exposure required for the locked-pin intervertebral distractor and the use of a table-based circular self-retaining soft-tissue retractor system. The keel cutting chisel can be safely used with this pin distractor/stabilizer in addition to a safety block mechanism (Fig. 5). Whether this semi-constrained device will afford a more optimal balance between motion preservation, ease and consistency of implantation, and neurological fitness has yet to be defined; however, we have noted no spontaneous autofusions or ectopic bone formation in our cases, and we have observed no approach- or device-related complications. Lastly, according to the manufacturer (Synthes Spine) in multiaxis simulator testing, the polyethylene wear rate for ProDisc-C was 40- to 50-fold less than the typical wear rate shown for hip and knee prostheses.

In our series, neck pain intensity and frequency showed a nonstatistically significant increase between 3 weeks and 1 year. We will closely monitor the clinical neck pain outcomes during the next several years. Of special interest in our clinical series was the presence of two patients who had undergone prior Bryan disc cervical arthroplasty and in whom there was recurrent adjacent-level disease. Magnetic resonance imaging revealed no evidence of any significant spondylotic changes at these adjacent levels to indicate preexisting changes in the discs. Whether these subsequent changes are a result of the arthroplasty technique or the natural history of the disease process, as discussed thoroughly by Hilibrand, et al.,⁴⁶ will be an ongoing topic of investigation and research.

Disclosure

Dr. Bertagnoli is a paid consultant and lecturer for Synthes Spine.

References

1. Abraham DJ, Herkowitz HN: Indications and trends in use in cervical spinal fusions. **Orthop Clin North Am** 29:731-744, 1998
2. Albert TJ, Murrell SE: Surgical management of cervical radiculopathy. **J Am Acad Orthop Surg** 7:368-376, 1999
3. Alemo-Hammad S: Use of acrylic in anterior cervical discectomy: technical note. **Neurosurgery** 17:94-96, 1985
4. Alvarez JA, Hardy RW Jr: Anterior cervical discectomy for one- and two-level cervical disc disease: the controversy surrounding the question of whether to fuse, plate, or both. **Crit Rev Neurosurg** 9:234-251, 1999
5. Anderson LD, Stivers BR, Park WI III: Multiple level anterior cervical spine fusion. A report of 16 cases. **J Trauma** 14:653-674, 1974
6. Anderson PA, Bohlman HH: Anterior decompression and arthrodesis of the cervical spine: long-term motor improvement. Part II—Improvement in complete traumatic quadriplegia. **J Bone Joint Surg Am** 74:683-692, 1992
7. Aronson N, Filtzer DL, Bagan M: Anterior cervical fusion by the Smith-Robinson approach. **J Neurosurg** 29:396-404, 1968
8. Bernard TN Jr, Whitecloud TS III: Cervical spondylotic myelopathy and myeloradiculopathy. Anterior decompression and stabilization with autogenous fibula strut graft. **Clin Orthop** 221:149-160, 1987
9. Bishop RC, Moore KA, Hadley MN: Anterior cervical interbody fusion using autogeneic and allogeneic bone graft substrate: a prospective comparative analysis. **J Neurosurg** 85:206-210, 1996
10. Bohlman HH, Anderson PA: Anterior decompression and arthrodesis of the cervical spine: long-term motor improvement. Part I—Improvement in incomplete traumatic quadriplegia. **J Bone Joint Surg Am** 74:671-682, 1992
11. Bolesta MJ, Rehtine GR II, Chrin AM: One- and two-level anterior cervical discectomy and fusion: the effect of plate fixation. **Spine J** 2:197-203, 2002
12. Bose B: Anterior cervical arthrodesis using DOC dynamic stabilization implant for improvement in sagittal angulation and controlled settling. **J Neurosurg (Spine 1)** 98:8-13, 2003
13. Bose B: Anterior cervical fusion using Caspar plating: analysis of results and review of the literature. **Surg Neurol** 49:25-31, 1998
14. Bose B: Anterior cervical instrumentation enhances fusion rates in multilevel reconstruction in smokers. **J Spinal Disord** 14:3-9, 2001
15. Brodke DS, Zdeblick TA: Modified Smith-Robinson procedure for anterior cervical discectomy and fusion. **Spine** 17 (Suppl 10):S427-S430, 1992
16. Busch G: Anterior fusion for cervical spondylosis. **J Neurol** 219:117-126, 1978
17. Caspar W, Geisler FH, Pitzen T, Johnson TA: Anterior cervical plate stabilization in one- and two-level degenerative disease: overtreatment or benefit? **J Spinal Disord** 11:1-11, 1998
18. Cherry C: Anterior cervical discectomy and fusion for cervical disc disease. **AORN J** 76:998-1012, 2002
19. Chesnut RM, Abitbol JJ, Garfin SR: Surgical management of cervical radiculopathy. Indication, techniques, and results. **Orthop Clin North Am** 23:461-474, 1992
20. Chitanondh H: Treatment of cervical disc herniation by anterior cervical discectomy and fusion with graft from bone bank. **J Med Assoc Thai** 57:328-332, 1974
21. Chowdhary UM, Carey PC: Anterior cervical decompression and fusion for cervical degenerative disc diseases. **Ir Med J** 78:243-247, 1985
22. Clements DH, O'Leary PF: Anterior cervical discectomy and fusion. **Spine** 15:1023-1025, 1990
23. Cloward RB: The anterior surgical approach to the cervical spine: the Cloward Procedure: past, present, and future. The Presidential Guest Lecture, Cervical Spine Research Society. **Spine** 13:823-827, 1988
24. Cummins BH, Robertson JT, Gill SS: Surgical experience with an implanted artificial cervical joint. **J Neurosurg** 88:943-948, 1998
25. DePalma AF, Rothman RH, Lewinnek GE, Canale ST: Anterior interbody fusion for severe cervical disc degeneration. **Surg Gynecol Obstet** 134:755-758, 1972
26. Emery SE: Cervical spondylotic myelopathy: diagnosis and treatment. **J Am Acad Orthop Surg** 9:376-388, 2001
27. Emery SE, Bohlman HH, Bolesta MJ, Jones PK: Anterior cervical decompression and arthrodesis for the treatment of cervical spondylotic myelopathy. Two to seventeen-year follow-up. **J Bone Joint Surg Am** 80:941-951, 1998
28. Emery SE, Bolesta MJ, Banks MA, Jones PK: Robinson anterior cervical fusion comparison of the standard and modified techniques. **Spine** 19:660-663, 1994
29. Emery SE, Fisher JR, Bohlman HH: Three-level anterior cervical discectomy and fusion: radiographic and clinical results. **Spine** 22:2622-2625, 1997

30. Epstein NE: Anterior cervical discectomy and fusion procedures. **Spine** 16:599, 1991
31. Fairbank JC, Couper J, Davies JB, O'Brien JP: The Oswestry low back pain disability questionnaire. **Physiotherapy** 66: 271–273, 1980
32. Fernstrom U: Arthroplasty with intracorporeal endoprosthesis in herniated disc and in painful disc. **Acta Chir Scand Suppl** 357:154–159, 1966
33. Gaetani P, Tancioni F, Spanu G, Rodriguez y Baena R: Anterior cervical discectomy: an analysis on clinical long-term results in 153 cases. **J Neurosurg Sci** 39:211–218, 1995
34. Geer CP, Papadopoulos SM: The argument for single-level anterior cervical discectomy and fusion with anterior plate fixation. **Clin Neurosurg** 45:25–29, 21, 1999
35. George B, Gauthier N, Lot G: Multisegmental cervical spondylotic myelopathy and radiculopathy treated by multilevel oblique corpectomies without fusion. **Neurosurgery** 44:81–90, 1999
36. Glynn MK, Pidgeon CN: Anterior fusion for cervical disc disease. **Ir J Med Sci** 151:249–252, 1982
37. Goffin J, Casey A, Kehr P, Liebig K, Lind B, Logroscino C, et al: Preliminary clinical experience with the Bryan Cervical Disc Prosthesis. **Neurosurgery** 51:840–847, 2002
38. Goffin J, Van Calenbergh F, van Loon J, Casey A, Kehr P, Liebig K, et al: Intermediate follow-up after treatment of degenerative disc disease with the Bryan Cervical Disc Prosthesis: single-level and bi-level. **Spine** 28:2673–2678, 2003
39. Gore DR, Sepic SB: Anterior cervical fusion for degenerated or protruded discs. A review of one hundred forty-six patients. **Spine** 9:667–671, 1984
40. Gore DR, Sepic SB: Anterior discectomy and fusion for painful cervical disc disease. A report of 50 patients with an average follow-up of 21 years. **Spine** 23:2047–2051, 1998
41. Guyer RD, Ohnmeiss DD: Intervertebral disc prostheses. **Spine** 28 (Suppl 15):S15–S23, 2003
42. Hacker RJ: A randomized prospective study of an anterior cervical interbody fusion device with a minimum of 2 years of follow-up results. **J Neurosurg (Spine 2)** 93:222–226, 2000
43. Hacker RJ, Cauthen JC, Gilbert TJ, Griffith SL: A prospective randomized multicenter clinical evaluation of an anterior cervical fusion cage. **Spine** 25:2646–2655, 2000
44. Heidecke V, Rainov NG, Burkert W: Anterior cervical fusion with the Orion locking plate system. **Spine** 23:1796–1803, 1998
45. Hilibrand AS, Carlson GD, Palumbo MA, Jones PK, Bohlman HH: Radiculopathy and myelopathy at segments adjacent to the site of a previous anterior cervical arthrodesis. **J Bone Joint Surg Am** 81:519–528, 1999
46. Hilibrand AS, Fye MA, Emery SE, Palumbo MA, Bohlman HH: Increased rate of arthrodesis with strut grafting after multilevel anterior cervical decompression. **Spine** 27:146–151, 2002
47. Hodges SD, Humphreys SC, Eck JC, Covington LA, Van Horn ER, Peterson JE: A modified technique for anterior multilevel cervical fusion. **J Orthop Sci** 7:313–316, 2002
48. Hunter LY, Braunstein EM, Bailey RW: Radiographic changes following anterior cervical fusion. **Spine** 5:399–401, 1980
49. Iseda T, Goya T, Nakano S, Kodama T, Moriyama T, Wakisaka S: Serial changes in signal intensities of the adjacent discs on T2-weighted sagittal images after surgical treatment of cervical spondylosis: anterior interbody fusion versus expansive laminoplasty. **Acta Neurochir** 143:707–710, 2001
50. Matsunaga S, Kabayama S, Yamamoto T, Yone K, Sakou T, Nakanishi K: Strain on intervertebral discs after anterior cervical decompression and fusion. **Spine** 24:670–675, 1999
51. Palit M, Schofferman J, Goldthwaite N, Reynolds J, Kerner M, Keaney D, et al: Anterior discectomy and fusion for the management of neck pain. **Spine** 24:2224–2228, 1999
52. Reitz H, Joubert MJ: Intractable headache and cervico-brachialgia treated by complete replacement of cervical intravertebral discs with a metal prosthesis. **S Afr Med J** 38:881–884, 1964
53. Robinson RA: The problem of neck pain: its alleviation by anterior removal of intervertebral disc with interbody fusion in the cervical spine. **J Med Assoc State Ala** 33:1–14, 1963
54. Rosenorn J, Hansen EB, Rosenorn MA: Anterior cervical discectomy with and without fusion. A prospective study. **J Neurosurg** 59:252–255, 1983
55. Sekhon LH: Cervical arthroplasty in the management of spondylotic myelopathy. **J Spinal Disord Tech** 16:307–313, 2003
56. Stefee A: The development and use of an artificial disk: case presentation. **Camp Back Issues** 2:4, 1989
57. van Limbeek J, Jacobs WC, Anderson PG, Pavlov PW: A systematic literature review to identify the best method for a single level anterior cervical interbody fusion. **Eur Spine J** 9:129–136, 2000
58. Wang JC, McDonough PW, Endow K, Kanim LE, Delamarer RB: The effect of cervical plating on single-level anterior cervical discectomy and fusion. **J Spinal Disord** 12:467–471, 1999
59. Wang MY, Green BA, Vitarbo E, Levi AD: Adjacent segment disease: an uncommon complication after cervical expansile laminoplasty: case report. **Neurosurgery** 53:770–773, 2003
60. Wigfield C, Gill S, Nelson R, Langdon I, Metcalf N, Robertson J: Influence of an artificial cervical joint compared with fusion on adjacent-level motion in the treatment of degenerative cervical disc disease. **J Neurosurg (Spine 1)** 96:17–21, 2002
61. Wigfield CC, Gill SS, Nelson RJ, Metcalf NH, Robertson JT: The new Frenchay artificial cervical joint: results from a two-year pilot study. **Spine** 27:2446–2452, 2002
62. Wigfield CC, Skrzypiec D, Jackowski A, Adams MA: Internal stress distribution in cervical intervertebral discs: the influence of an artificial cervical joint and simulated anterior interbody fusion. **J Spinal Disord Tech** 16:441–449, 2003
63. Yang KC, Lu XS, Cai QL, Ye LX, Lu WQ: Cervical spondylotic myelopathy treated by anterior multilevel decompression and fusion. Follow-up report of 214 cases. **Clin Orthop** 221: 161–164, 1987

Manuscript received April 6, 2004.

Accepted in final form October 28, 2004.

Address reprint requests to: James J. Yue, M.D., Department of Orthopaedic Surgery and Rehabilitation, Yale University School of Medicine, 800 Howard Avenue, P.O. Box 208071, New Haven, Connecticut 06520. email: james.yue@yale.edu.